



## Dedication to Dr. Mark Swendrowski

(June 13, 1948 - December 28, 2020)



We would like to dedicate this new bulletin in memory of Dr. Mark Swendrowski.

Mark was born in Penley Hall, Wales in 1948. In 1956, he and his family immigrated to Canada, making Regina their home. Mark went to high school at Campion College. He completed his Doctor of Veterinary Medicine from the Western College of Veterinary Medicine in 1975, and returned five years later to study veterinary pathology. In 1982, Mark moved with his family to Winnipeg to start his job with Veterinary Diagnostic Services (VDS). He was the laboratory manager from 2004 to 2012. In 2012, Mark received the

Canadian Animal Health Laboratorians Network (CAHLN) Laboratorian of the Year Award for his many contributions to veterinary laboratory medicine in Canada. Mark was an outstanding diagnostician and educator. He was awarded the Life Member distinction from the Manitoba Veterinary Medical Association in 2016 in recognition of his contributions to animal health in Manitoba. He formally retired from VDS in 2014, but returned in 2018 part-time focusing on surgical pathology.

Mark was a great pathologist with a wealth of knowledge and experience and an incredible sense of humour. During his long career, Mark was a mentor to all of the anatomic and clinical pathologists at our laboratory. His attention to detail, great observation skills, and willingness to research were priceless. He was loved and appreciated and is remembered by many in the Canadian veterinary community.

Dr. B. Bryan, Dr. N. Pople, Dr. M. Tomczyk

## New LIMS System

VDS is in the development of a new Laboratory Information Management System (LIMS) for case submissions, reporting test results and invoices. The new system is an effort to modernize client services, which will include web-based submissions for clients, enhanced billing capabilities, and easier ability to retrieve and analyze data, to benefit clinicians and livestock industries. The system is expected to launch in 2023.

### Holiday Closures

VDS will be closed on the following days:

- December 26, 2022
- December 27, 2022
- January 2, 2023

### VDS Team

Dr. Scott Zaari – Chief Veterinary Officer  
Shannon Korosec – VDS Manager  
Dr. Md Niaz Rahim – Molecular Biologist  
Dr. Neil Pople – Anatomic Pathologist/ Veterinary Microbiologist  
Dr. Marek Tomczyk – Anatomic Pathologist  
Dr. Brenda Bryan – Anatomic Pathologist  
Dr. Karlyn Bland – Clinical Pathologist  
Cheryl Friday – Supervisor, Microbiology  
Tracy Scammell-LaFleur – Supervisor, Virology  
Rhonda Gregoire – Supervisor, Clinical Pathology  
Agnieszka Gigiel – Supervisor, Accessioning  
Genedine Quisumbing – Quality Assurance Officer  
Ade Opanubi – Administration Officer  
Sharon Niebel – SAP/Revenue Clerk  
Lindsay McDonald Dickson – SAP Clerk  
Barb Bednarski – Client Services Coordinator/Reception

# VDS Staff Spotlight

## Shannon Korosec, Acting Manager



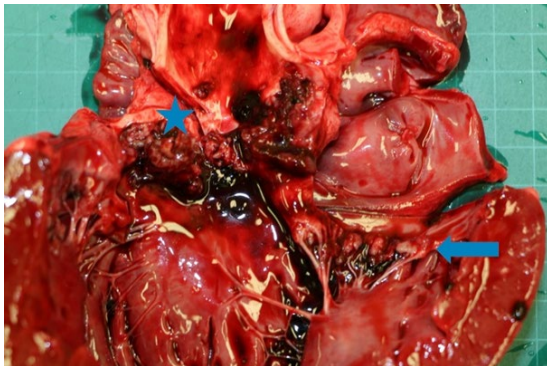
Shannon started her career as a medical laboratory technologist at St. Boniface hospital in 2004 where she spent 14 years in clinical microbiology. During her time there, she moved into a senior technologist position which heavily focused on quality management. She has performed audits for the College of American Pathologists and Shared Health.

Shannon came to VDS in the fall of 2018 to supervise the clinical Microbiology lab. During this time, she led the validation and implementation of MALDI-TOF Mass Spectrometry and the development of a robust quality control system in preparation for ISO 17025 accreditation.

She became acting manager of the lab in July 2022. Shannon is excited to continue developing and strengthening relationships with colleagues and stakeholders, and looks forward to implementing the new LIMS system, obtaining ISO 17025 accreditation and creating service enhancements to our valued clients.

# Valvular Endocarditis and Endocardiosis in a Dog

## Dr. Marek Tomczyk, DVM, Dipl. Anat. Path, VDS Pathologist



**Picture (above):** Left ventricle opened. Blue Star - Irregular vegetations forming a multinodular mass on the aortic valves (endocarditis). Blue Arrow - Thickenings on the mitral valve and chordae tendinae attachments (endocardiosis). Photo courtesy of Dr. Marek Tomczyk.

In June of 2022, the Veterinary Diagnostic Services (VDS) in Winnipeg received the body of a five year old, intact, male dog who had recent episodes of lethargy, anorexia and vomiting. The animal died suddenly at home.

On post mortem, his lungs were marbled pink red to dark red and showed rib imprints due to enlargement. The heart had a round shape. Eight thickenings, up to 0.4 cm in diameter, were present at the point of attachment between the mitral valve and the chordae tendinae. A thick layer of yellow red, irregular vegetations covered the aortic valves.

This multinodular mass was obstructing blood outflow from the left ventricle to the aorta. The left to right ventricle ratio was 4:1.

The mitral valve thickening and inflammatory process affecting the aortic valve reduced blood flow through the left ventricle, causing hemorrhage and pulmonary edema (fluid on the lungs). This led to hypoxia (low tissue oxygen levels), anoxia (complete oxygen depletion) and death. The infection of endocardial tissue is relatively uncommon in small animals and usually involves the aortic and/or mitral valves in dogs. In this case, the aortic valves were affected by a bacterial process. The most common bacterial pathogens for endocarditis include Streptococcus species, Staphylococcus aureus, Escherichia coli, while Bartonella species, Erysipelothrix rhusiopathiae, Pseudomonas aeruginosa and Pasteurella multocida are less frequently encountered. The root cause of the endocarditis was not determined due to further testing not being requested.

## New VDS Staff

- Dr. Vasyil Shpyrka  
*Veterinary Pathologist*
- Tobi Menard  
*Medical Technologist*
- Sarah Peters  
*Medical Technologist*

## Staff Retirements



**Irene Bayne**  
*Microbiology Medical Laboratory Technologist*

After 25 years with VDS, Irene is now retiring.

Irene graduated from Medical Laboratory in 1980, then started right away at the Provencher Medical Diagnostic Laboratory, a private lab owned by St. Boniface Hospital pathologists and worked there until 1995. She also worked at Envirotec Laboratories until 1997 and in 1998 started at VDS. And the rest is history.

Irene has not decided what her retirement will hold, but does plan to volunteer at her mother's former personal care home and relax a while. We thank her for her hard work and dedication and wish her the best in her retirement.

## Lab Submission Fees

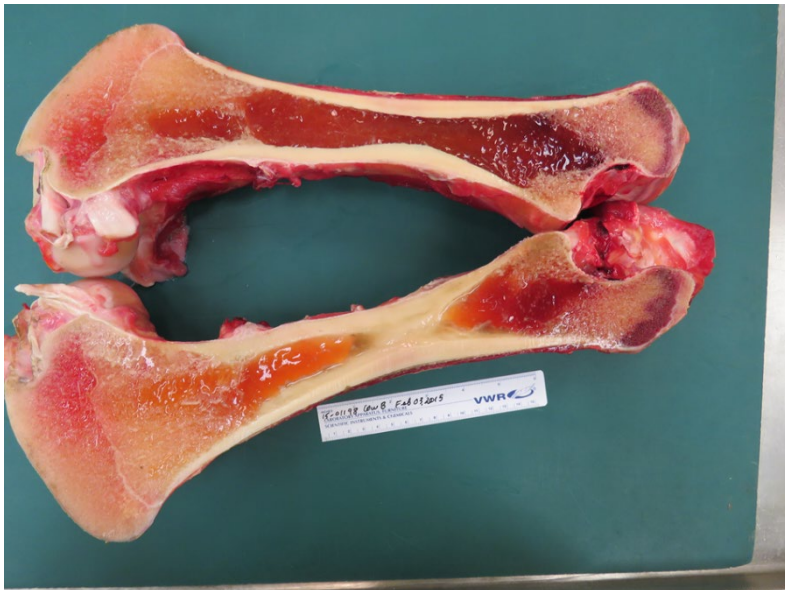Please note that a fee schedule update will occur in 2023, with more information to follow in the New Year.

# Downer Cow with Serous Atrophy of Fat

Dr. Brenda Bryan, DVM, MVetSc, VDS Pathologist

During the winter, a cow was found to be weak and unable to rise, resulting in her humane euthanasia and submission for necropsy to VDS.

On post mortem, the cow was determined to have a body condition score of 1 out of 5, with prominent and palpable vertebrae and ribs. A generalized depletion of body fat stores and serous atrophy of fat (the replacement of fat with a gelatinous material) were noted. This change was most evident around the kidney, coronary groove of the heart, and bone marrow. The skeletal muscles were soft, red, friable (easily crumbled), and wet. The dehydrated bone marrow fat percentage was estimated to be 6 percent.



**Picture (above):** The yellow, gelatinous change to the femur bone marrow (serous atrophy of fat).

Photo courtesy of Dr. Brenda Bryan

Microscopic examination revealed that a pale pink granular material had replaced the normal, large lipid vacuole within the bone marrow adipocytes (fat cells) and the adipocyte cell membranes appeared shrunken and irregular.

The estimated dehydrated bone marrow fat percentage was much lower than the 80 percent normally noted. Due to the body using fat stores sequentially, with external fat being used first, followed by deep organ fat and then bone marrow, the extremely low bone marrow fat percentage indicated that the downer condition was due to prolonged energy and protein malnutrition. This occurs when caloric expenditures exceed caloric intake, leading to the depletion of fat stores and protein mobilization from muscles for energy. It results in skeletal and cardiac muscle weakness and serous atrophy of fat. Diagnostic testing did not detect the presence of a chronic disease process, such as Bovine Spongiform Encephalopathy (BSE) or Bovine Viral Diarrhea Virus (BVDV).

This case highlights the importance of routine body condition scoring that incorporates palpation, especially for animals having thick coats or wool. It is an essential tool aiding in the management of livestock that have increased energy requirements due to their exposure to extreme cold conditions.

Happy Holidays from everyone at Manitoba Agriculture's Animal Health and Welfare Branch!



Photo courtesy of Pawparazzi Pet Photography

## Veterinary Diagnostic Services Contact Information

Accounts Payable:  
[agrinvoices@gov.mb.ca](mailto:agrinvoices@gov.mb.ca)

Clinical Pathology:  
[clinpath@gov.mb.ca](mailto:clinpath@gov.mb.ca)

Microbiology (Bacteriology/ Mycology/Parasitology):  
[microbiology@gov.mb.ca](mailto:microbiology@gov.mb.ca)

Virology (PCR/Molecular Diagnostics/Serology):  
[virology@gov.mb.ca](mailto:virology@gov.mb.ca)

545 University Crescent  
Winnipeg, Manitoba R3T 5S6

Phone: 204-945-8220

Email: [vetlab@gov.mb.ca](mailto:vetlab@gov.mb.ca)

Web: [manitoba.ca/agriculture/vds](http://manitoba.ca/agriculture/vds)